

Extractions



Dr. Angelica (Angie) Bebel, DVM, DAVDC
West Coast Veterinary Dental Services,
Vancouver, B.C
Email: tembo4444@gmail.com
Office Telephone: 604-473-3605

1

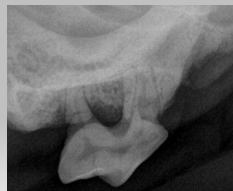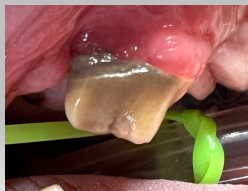Indications

- Periodontitis
- Pulp Necrosis
- Dental Fractures
- Tooth Resorption
- Retained tooth root remnants
- Feline Chronic Gingivostomatitis
- Deciduous Teeth
- Supernumerary Teeth
- Unerupted Teeth
- Malocclusions/Abnormally positioned teeth

2

Indications

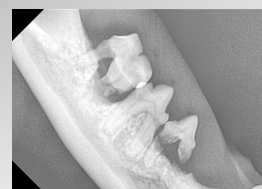
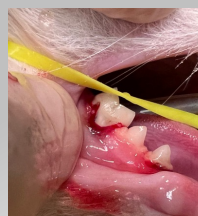Periodontitis



3

Indications

Periodontitis

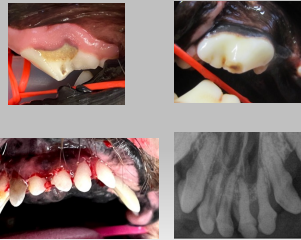

4

Indications

Pulp necrosis

- a. Direct (CCF)
- b. Indirect (UCF, AT, AB)
- c. Irreversible pulpitis (discoloured tooth, intact)
- d. Secondary to malformations

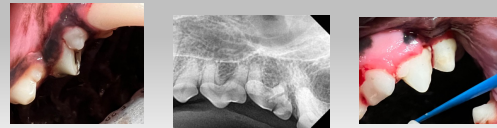

5

Indications

Dental Fractures

- a. UCF (uncomplicated crown fractures) – enamel-dentin fracture, treatment for those that have resulted in pulp necrosis
- b. CCF (complicated crown fractures) – enamel – dentin fracture with pulp exposure
- c. CCRF (complicated crown and root fracture)
- d. CRF (complicated root fracture)



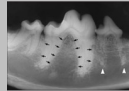
6

Indications

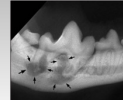
Tooth resorption

- Extraction is recommended – for those with intact roots
- Specific treatment for those with end stage root resorption
- Not just a feline condition, seeing more commonly in dogs
 - o Age-related root resorption, seen in up to 43% of dogs aged 12-14 years (1990 article)
 - o Radiographic evaluation of the types of tooth resorption in dogs (Dr. Peralta and Vestraete): TR detected in 54% of dogs; more frequent amount in older and large bodied dogs
 - o two most common types: ERR and EIR (34 % and 26%)

External Replacement Resorption, ERR



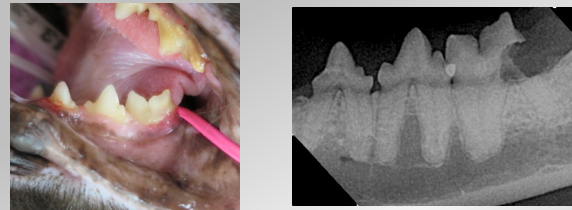
External Inflammatory Resorption (EIR)



7

Indications

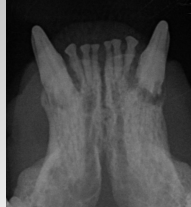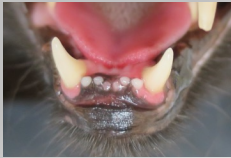Feline tooth resorption TYPE 1 Extraction



8

Indications

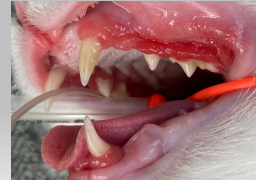Feline tooth resorption – Type 2
Subgingival Coronectomy/Crown Amputation



9

Indications

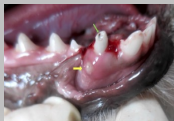Feline Chronic Gingivostomatitis



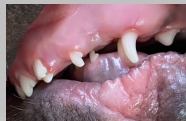10

Indications

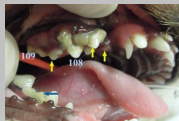Deciduous Teeth



a. Fractured teeth



b. Interceptive orthodontics due to malocclusions

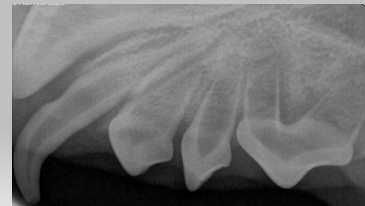


c. Persistent deciduous teeth

11

Indications

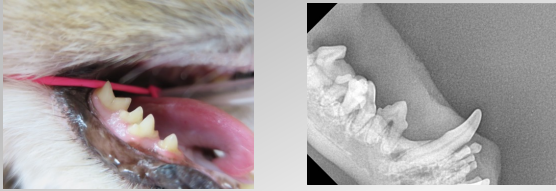Supernumerary teeth



12

Indications

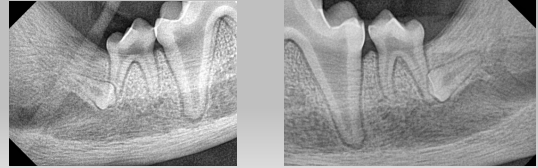
Supernumerary teeth



13

Indications

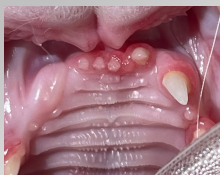Unerupted Teeth



14

Indications

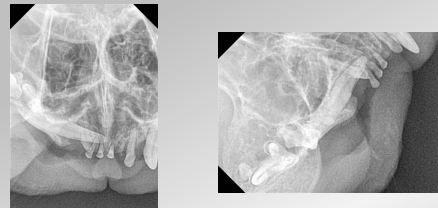
Unerupted Teeth



15

Indications

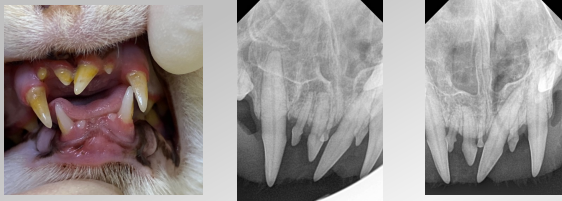
Unerupted Teeth



16

Indications

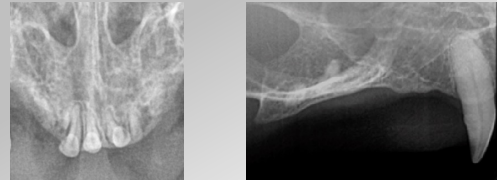Malocclusions/Abnormally Positioned Teeth



17

Indications

Retained root remnants



18

Clinical Examination of Teeth for Extraction

Tooth mobility

- increased mobility may be associated with:
 - extensive bone loss
 - Root fracture

Crown condition

- Those with resorption will fracture

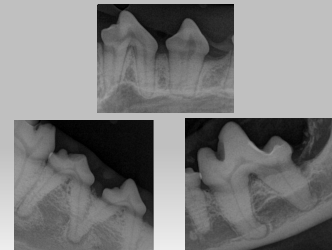

19

Radiographic Examination of Teeth for Extraction

Root configuration

- Fused roots
- Supernumerary roots
- Hypercementosis
- Root dilacerations
- Root fractures



20

Radiographic Examination of Teeth for Extraction

Proximity to adjacent teeth and other important structures

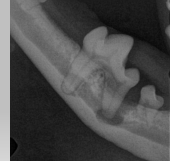- Bone removal if necessary, preserve the adjacent teeth and roots
- Deciduous teeth and permanent buds
- Infraorbital neurovascular bundles – the foramen dorsal to the distal root of the 107, 207
- Major palatine artery
- Parotid salivary duct, zygomatic,
- Maxillary recess - lateral diverticulum of the nasal cavity, the opening of which lies in a transverse plane through the mesial roots of the maxillary fourth premolar tooth.⁵⁸ It is possible to dislodge a root into this recess if excessive force is used during extraction attempts. In brachycephalic breeds, the orbit lies directly dorsal to the maxillary fourth premolar, first molar and second molar teeth.
- Orbital penetration has been reported during attempts to extract teeth

21

Radiographic Examination of Teeth for Extraction

Quality of the surrounding bone

- Density can give indication if the extraction may be more challenging
- Periapical lucencies and iatrogenic trauma (409, 309)
–small breed to large breed
- Cysts

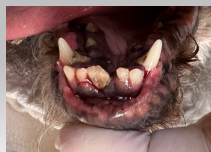

22

Treatment Planning

Simple extractions (closed, uncomplicated, non-surgical)

- Incise only the gingival sulcus
- No incision into the attached gingiva or tooth sectioning
- Single rooted teeth

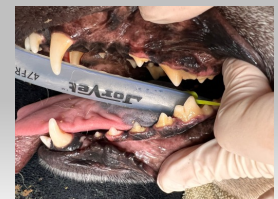

23

Treatment Planning

Surgical Extractions (open or complicated extraction)

- Gingival incision
- Bone removal
- Sectioning of the tooth
- Most multi-rooted teeth, canine, maxillary third incisors

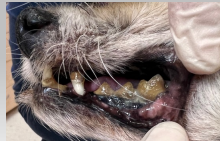


24

Treatment Planning

Consider clinical findings when choosing simple versus surgical:

- Mobility
- Radiographic findings of bone loss or root morphology, attachment
- These may allow you to use a simple extractions
- However, best to always section teeth

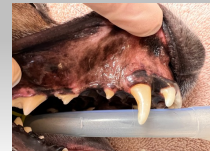

25

Flap Design

Goals

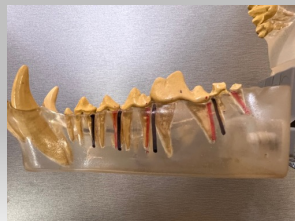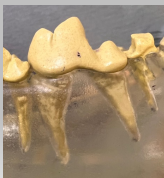- Sufficient size to allow surgical site exposure
- Base of flap
- Be aware of vital structures (infraorbital, mental)
- Vertical releasing incisions – made at line angles, divergent/oblique
- Edges - over bone when finished



26

Flap Design

Line Angles



27

Flap Design

Equipment

1. # 15 scalpel blade and handle

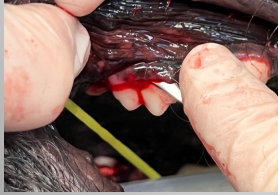

2. Periosteal Elevator



28

Flap Design Equipment



2. Periosteal Elevator

EX 7



EX 19

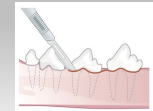
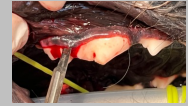

29

Flap Design

Sulcular Incision

- Free the gingival attachment from the tooth providing increased visualization
- In some severe perio cases, some may recommend excising the free gingiva (1-2 mm not attached to the tooth) and the pocket epithelium instead of incising
- No published studies saying that this leads to more rapid healing of the extraction sites, in people some suggestion that the bone regeneration may occur more rapidly in these cases

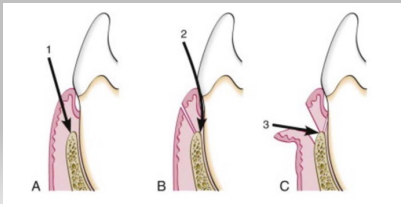


Luxman ML, Verstraete RM. Principles of Endodontics in: Verstraete RM, Luxman ML, Brouwerhoff AL, eds. Oral and Maxillofacial Surgery in Dogs and Cats. Edinburgh: Elsevier Ltd; 2012:412-43.

30

Flap Design

A) Internal or reverse bevel B) Sulcular Incision C) Interdental



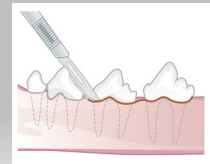
Luxman ML, Verstraete RM. Principles of Endodontics in: Verstraete RM, Luxman ML, Brouwerhoff AL, eds. Oral and Maxillofacial Surgery in Dogs and Cats. Edinburgh: Elsevier Ltd; 2012:412-43.

31

Flap Design

Gingival Flaps

- Envelope flap
- not extending apical to the mucogingival junction
 - created by making a sulcular incision and elevating some of the attached gingiva on the lingual and buccal aspects
 - no vertical releasing incisions
- Extended Envelope flap
- For extraction of several adjacent teeth



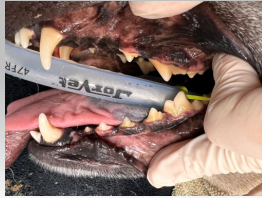Luxman ML, Verstraete RM. Principles of Endodontics in: Verstraete RM, Luxman ML, Brouwerhoff AL, eds. Oral and Maxillofacial Surgery in Dogs and Cats. Edinburgh: Elsevier Ltd; 2012:412-43.

32

Flap Design

Mucogingival Flaps

- When more exposure is required or a single tooth is being extracted
- Extending apical to the mucogingival junction
- Full thickness which include the periosteum
- Two types



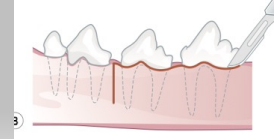
33

Flap Design

Mucogingival Flaps

Triangle Flap

- Single releasing flap
- Three cornered flap
- Sulcular incision and one vertical releasing incision
- Three cornered flap



Lutman ML, Verstraete FJM. Principles of Endodontics in Veterinary F&M, Lutman ML, Beuclerkhout AL, eds. Oral and Maxillofacial Surgery in Dogs and Cats. Edinburgh: Elsevier; 2012:223-40.

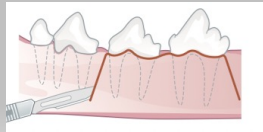
34

Flap Design

Mucogingival Flaps

Pedicle Flap

- Four cornered/double releasing flap
- Sulcular incision with two vertical releasing incisions
- Maximum exposure for removal of buccal alveolar bone for a challenging extraction or retrieval of a fractured root fragment.

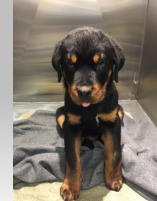



35

Bone Removal

Alveolotomy or partial alveolectomy

(Buccal bone removal)



36

Extractions

Tooth Sectioning

Equipment

- Carbide burs

- Pear: 329, 330 (cats, small dogs)
- Taper fissure cross-cut: 701, 701 surgical length versus 701 L (long) (medium to large dogs)



pear



700



701 L



701 SL

DentalSupplyUSA

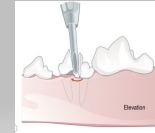
37

Extractions

Luxation vs Elevation

Elevator:

- Used as a lever, transmitting rotational forces from the handle to the blade
- Three parts - handle, shank and blade
- Blade - concave surface
- Different types
 - winged elevator (most common)
 - the winged blades available in various sizes, 1.5-, 2.5-, 3.5- and 4.5-mm widths
 - conform to roots of various circumference achieving better purchase on the tooth surface
 - if too much torque is placed on small teeth, root fracture may occur, so care must be employed.



Lawrence M. Weinstein PhD, Principles of Endodontics for Veterinary Dentists, Lawrence M. Weinstein DVM, MS, PhD, and International Society for Dental and Oral Care, Edinburgh, Scotland, UK, 2012, 348 pp.



Denmatix

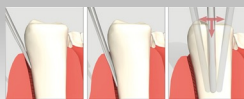38

Extractions

Luxation vs Elevation

Luxator:

- Sharp instrument, less concave blade
- Cuts or severs the fibers in the PDLs
- Shank and blade placed parallel to the root surface and tip pushed apically into alveolar socket to expand the bone space
- Straight, inner curve, outer curve
- No rotation



https://www.physiotherapy.com/author/patrickmccord/product_41-000



Denmatix

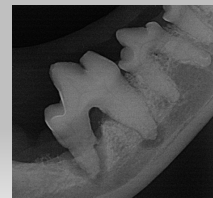39

Extractions

Luxation vs Elevation

Mechanical Principles to remove a tooth:

- Wedge principle - luxator
- Wheel-and-axle motion - elevator
- Leverage
- Rotation
- Traction

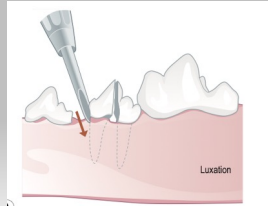


40

Extractions

Mechanical principles to remove a tooth

- Wedge principle – luxator
- Expands the bone space



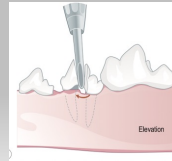
Lummen MJ, Versteegh FAM. Principles of Endodontics in: Versteegh FAM, Lummen MJ, Brouwerink AJ, eds. Oral and Maxillofacial Surgery in Dogs and Cats. Edinburgh: Elsevier Ltd; 2012:433-43

41

Extractions

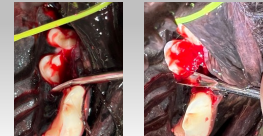
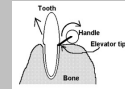
Mechanical principles to remove a tooth

- Wheel – and- axle motion (elevator)



Lummen MJ, Versteegh FAM. Principles of Endodontics in: Versteegh FAM, Lummen MJ, Brouwerink AJ, eds. Oral and Maxillofacial Surgery in Dogs and Cats. Edinburgh: Elsevier Ltd; 2012:433-43

- Modified wheel and axle

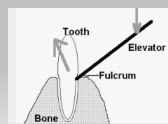


42

Extractions

Mechanical principles to remove a tooth

- Lever (Fulcrum)



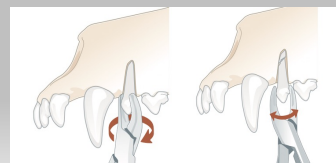
Toothfast.co

43

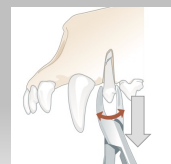
Extractions

Mechanical principles to remove a tooth

- Rotation



- Traction



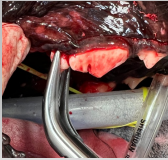Lummen MJ, Versteegh FAM. Principles of Endodontics in: Versteegh FAM, Lummen MJ, Brouwerink AJ, eds. Oral and Maxillofacial Surgery in Dogs and Cats. Edinburgh: Elsevier Ltd; 2012:433-43

44

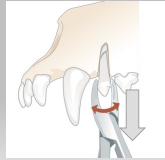Extractions

Mechanical principles to remove a tooth

- Rotation



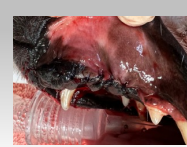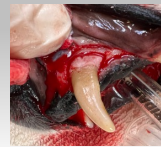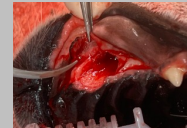
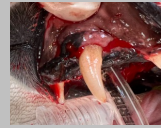- Traction



45

Extractions

Maxillary Canines

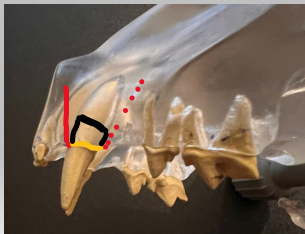


46

Extractions

Maxillary Canines

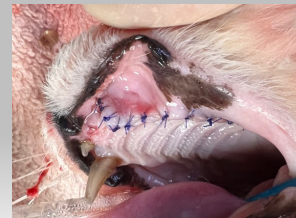- Gingival sulcus ———
- Flap incisions
 - Single releasing ———
 - Double releasing •••••
- Osteoplasty



47

Extractions

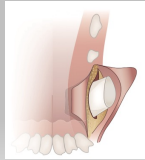
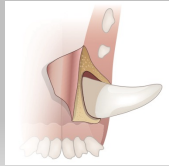
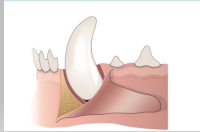
Maxillary Canines



48

Extractions

Mandibular Canines



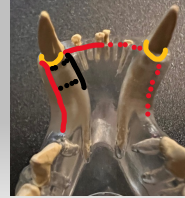
Loomer M, Verstraete FJM. Principles of Endodontics for Veterinary FOM. Loomer M, Verstraete FJM, eds. Oral and Maxillofacial Surgery in Dogs and Cats. Edinburgh: Elsevier; 2013:223-24.

49

Extractions

Mandibular Canines

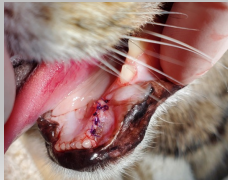- Gingival sulcus —
- Flap incisions
 - Lingual approach —
- Osteoplasty —



50

Extractions

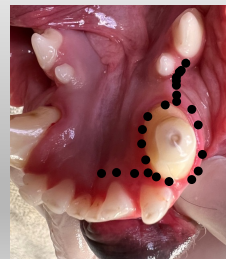
Mandibular Canines



51

Extractions

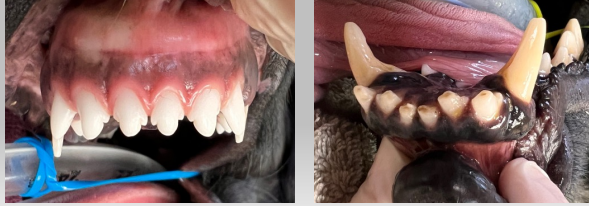
Mandibular Canines



52

Extractions

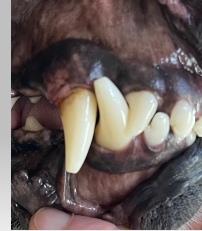Maxillary and Mandibular Incisors



53

Extractions

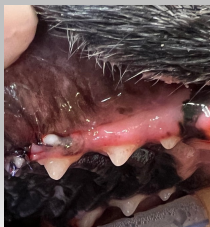Maxillary Third Incisors



54

Extractions

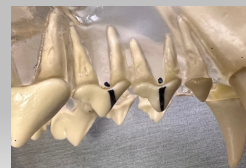Premolars



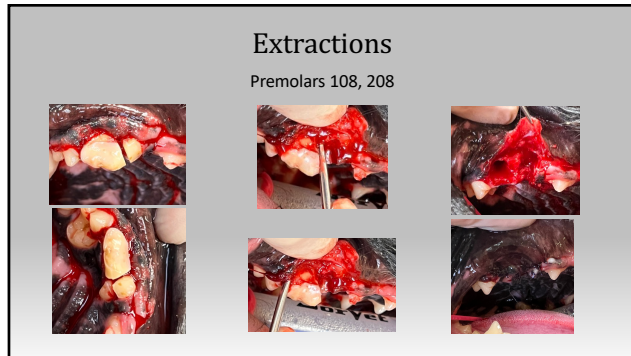
55

Extractions

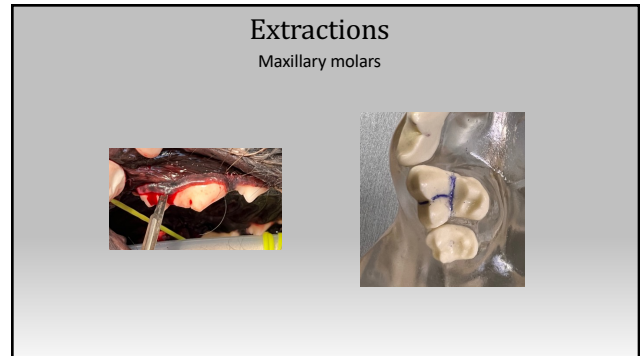
Premolars 06, 07, mandibular 08



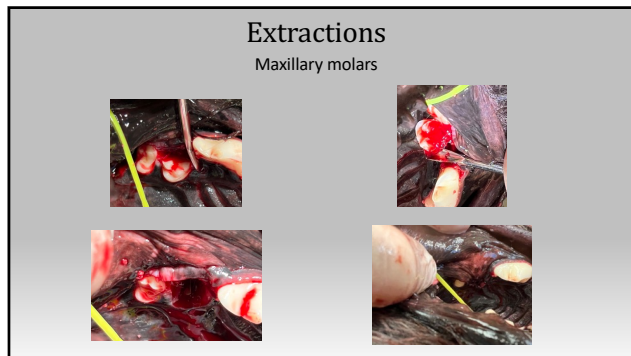
56



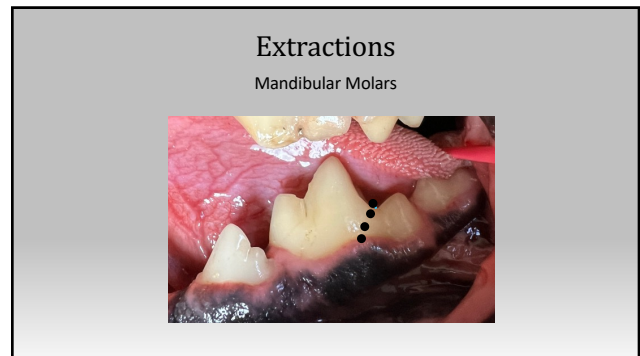
57



58



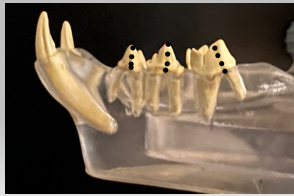
59



60

Extractions

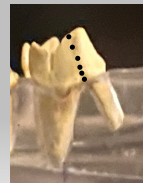Premolars - Mandibular



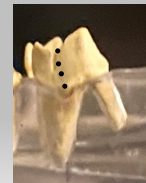61

Extractions

Premolars - Mandibular



right




wrong

62

Post - Extraction

Alveoloplasty

- Removal of sharp bone edges
 - Delay healing
 - Discomfort
 - Dehiscence
- Diamond burs
 - Round
 - Pear shape
 - Red (fine), green (course)



Dentaluggs.com

63

Post - Extraction

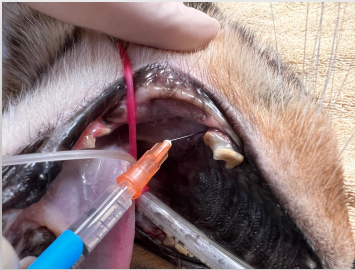Alveolus

- Cleared of debris
- Gentle curettage
 - Removal of pocket epithelium, remnants of calculus, granulation tissue
 - Be gentle - Don't want to disturb the blood clot
- Gentle lavage of the site with sterile saline

Packing - is it necessary?

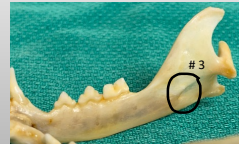64

Nerve Blocks

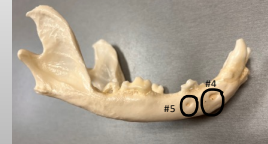

69

Nerve Blocks



#3 Mandibular : intraoral or extraoral

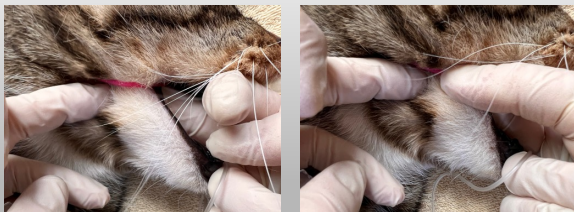


#4 – Middle mental foramen - only in medium large breed dogs
- distal root of second premolar
#5 – Caudal mental foramen – sometimes can palpate this

70

Nerve Blocks

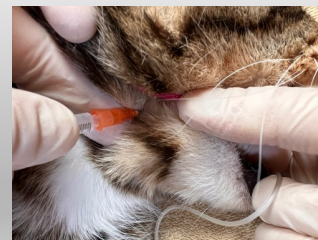
Extraoral



71

Nerve Blocks

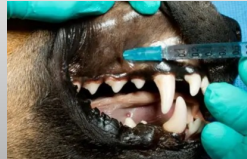
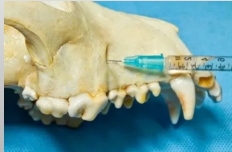Extraoral



72

Nerve Blocks

Canine - Infraorbital

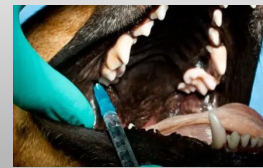
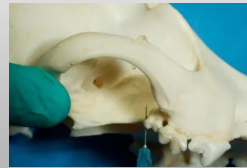
<https://veterinarydentistry.net/dental-nerve-blocks-dogs-cats/>

73

Nerve Blocks

Canine - Maxillary

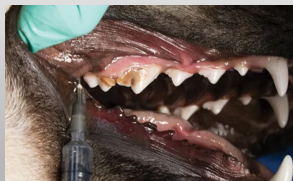


<https://veterinarydentistry.net/dental-nerve-blocks-dogs-cats/>

74

Nerve Blocks

Canine - Maxillary

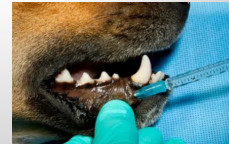
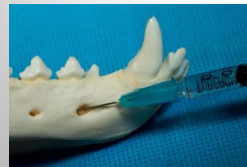
<https://veterinarydentistry.net/dental-nerve-blocks-dogs-cats/>

75

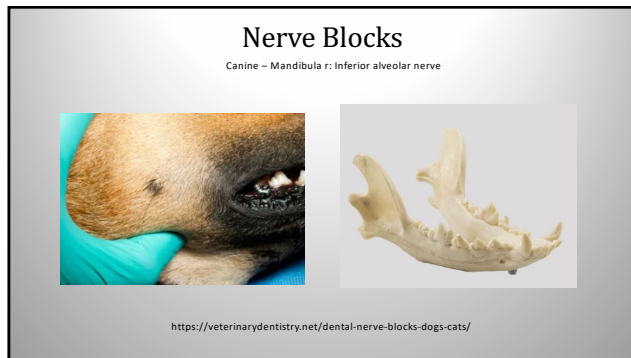
Nerve Blocks

Canine - Mental

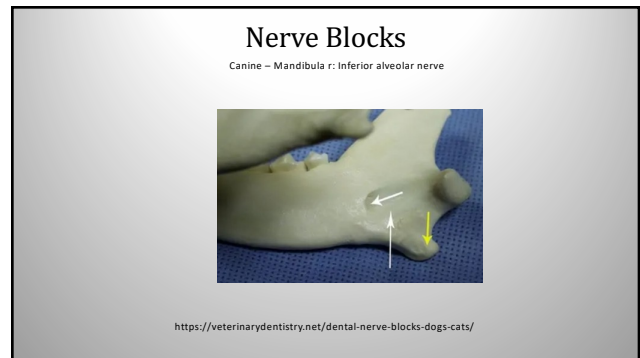


<https://veterinarydentistry.net/dental-nerve-blocks-dogs-cats/>

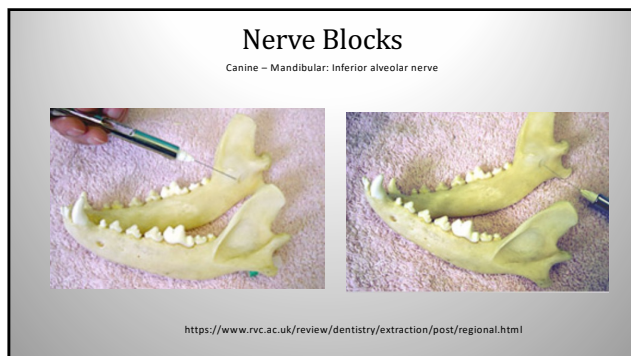
76



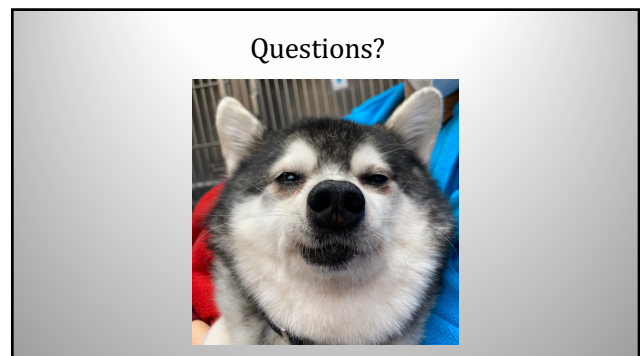
77



78



79



80